



PATIENT

Zephyr SDRO

SPECIES

Canine

BREED

Chihuahua

SEX

Male Neutered

AGE

11 years

WEIGHT

9.6lbs

INTERPRETED BY

Maggie Machen Lamy,
DVM, DACVIM
(Cardiology)

IMAGING PERFORMED BY

Jessica Bailes

HOSPITAL NAME

All Creatures Great &
Small Veterinary
Clinic

REFERRING VET

Dr. Litalien

INVOICE

22635

DATE

2/17/22

PRESENTING CLINICAL SIGNS

History: Obtained from previous owner 2 weeks ago, since then foster concerned about sneezing/upper airway congestion and coughing. Grade 4-5/6 heart murmur.

-Bloodwork/urinalysis performed 2/10/22: Chem: glob 3.8 (1.6-3.6) PSL 177 (24-140) creat 0.6 T4: 1.2 HWT: neg UA: USG - 1.024, pH - 8.0, trace protein, quiet sediment.

ECHOCARDIOGRAM FINDINGS

2D, m-mode, color flow and doppler imaging is available. Diffuse thickening of mitral valve leaflets with mild prolapse into the left atrial lumen. Mild to moderate eccentric mitral regurgitation with mild left atrial dilation. Normal MR velocity. Normal LV diameter with adequate myocardial function. The tricuspid valve appears mildly thickened with mild tricuspid regurgitation. Normal right atrial and ventricular diameter and morphology indicating no overt evidence of pulmonary arterial hypertension. The pulmonic and aortic valves are normal in morphology and mobility. Normal pulmonic and aortic outflow velocities with laminar flow. No obvious aortic or pulmonic insufficiency. No pericardial or pleural effusion noted. No obvious cardiac masses.

CARDIAC CHART

CANINE CARDIAC PARAMETERS	MR VMAX (m/s)	TR VMAX (m/s)	LA/AO (Boon method)	LA/AO (Heart Base; Swe)	FS (%)	EF (%)	EPSS (cm)
NORMAL PARAMETER	4.5-5.5	<2.7	1.3	<1.6	28-40	40-100	<0.6
PATIENT	5.2	NM	1.2	1.5	46	78	0.14
CANINE CARDIAC PARAMETERS	HR (BPM)	AV VMAX (m/s)	PV MAX (m/s)	BODY WEIGHT (kg)	LA 2D short axis Base view (cm)	LVIDd Avg: 2D and m-mode short axis (cm)	LVIDs Avg: 2D and m-mode short axis (cm)
NORMAL PARAMETER	50-100	0.7-1.7	0.7-1.6	BELOW	BELOW	BELOW	BELOW
PATIENT	NM	1.3	0.92	4.4	1.67	2.7	1.5
*Normal chamber parameters expressed as a mean value (SD)				3	1.27 (5.3)	2.46 (2.46)	1.36 (5.5)
BODY WEIGHT DEPENDENT PARAMETERS				5	1.40 (4.5)	2.74 (5.2)	1.60 (4.7)
<i>*Note: All measurements based upon multi-modal images and methods. An average value is reported.</i>				10	1.50 (3.8)	3.27 (3.5)	2.06 (3.1)
				15	1.83 (2.0)	3.71 (2.4)	2.43 (2.1)
				20	2.02 (1.9)	4.14 (2.2)	2.80 (2.0)
				25	2.18 (2.4)	4.48 (2.9)	3.10 (2.5)
				30	2.33 (3.3)	4.83 (3.9)	3.39 (3.4)
				35	2.48 (4.3)	5.17 (5.0)	3.69 (4.5)
				40	2.62 (5.2)	5.48 (6.1)	3.96 (5.4)
				50	2.88 (7.1)	6.07 (8.3)	4.46 (7.4)

INTERPRETATION OF THE FINDINGS & FURTHER RECOMMENDATIONS

Chronic degenerative valve disease causing mild to moderate mitral and mild tricuspid regurgitation. Lack of significant left atrial enlargement indicates the current risk for complication is low. No concurrent issues such as systolic dysfunction or pulmonary hypertension are noted in this study.



PATIENT

Zephyr SDRO

Given these findings, the cough is unlikely to be cardiac in origin and primary respiratory causes should be considered. Consider further respiratory work up/treatment (hydrocodone, taper course of steroids, Enrofloxacin, TTW/BAL, etc.).

SPECIES

Canine

In a dog with no significant left atrial enlargement, no cardiac medications are clearly indicated. Assessment of progression in the future will help predict long term prognosis, which is highly variable at this stage (B1). Omega fatty acid supplementation and mild salt restriction may be of some long-term benefit. Monitor for development of a cough, labored breathing, exercise intolerance or collapse episodes.

BREED

Chihuahua

Anesthetic risk is considered mild if needed. Cardiac protective drug choices (opioid/benzodiazepine premedication, propofol or alfaxalone induction, isoflurane gas) are recommended. Pre-oxygenate for 5-10 minutes prior to induction. Monitor for arrhythmias, hypotension, and hypoxia both intra and post-operatively and intervene as necessary. Mild IV fluid restriction is recommended to avoid fluid overload. Avoid heart rate stimulating drugs such as atropine unless clinically indicated.

SEX

Male Neutered

AGE

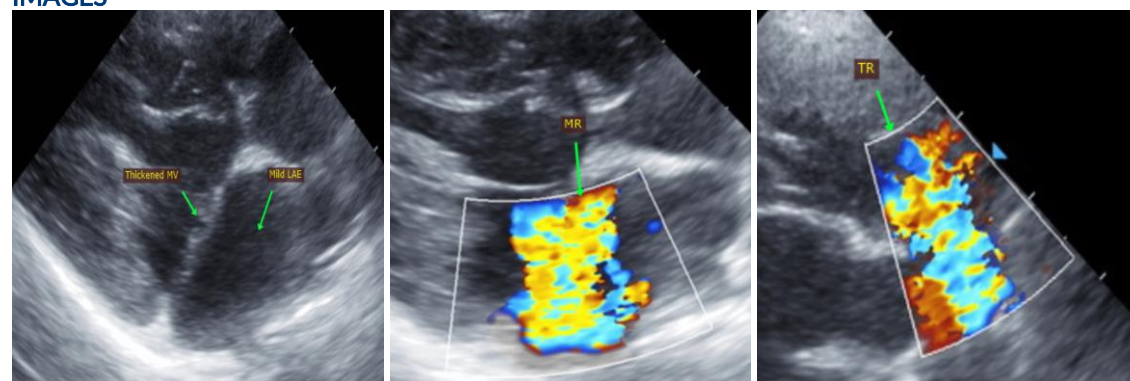
11 years

Recommend conservative monitoring with a recheck echocardiogram in 6 months, sooner if any development of clinical signs.

WEIGHT

9.6lbs

IMAGES



INTERPRETED BY

Maggie Machen Lamy,
DVM, DACVIM
(Cardiology)

IMAGING PERFORMED BY

Jessica Bailes

HOSPITAL NAME

All Creatures Great &
Small Veterinary
Clinic

The information and recommendations provided are based on the images presented by the referring veterinarian. No evaluation can be communicated regarding pathology that was not visible in the image/video clips provided.

REFERRING VET

Dr. Litalien

Thank you for this referral. This report was generated using transcription software, and minor dictation errors may be present. If the clinical or image interpretation does not parallel your findings or if I can be of any further assistance, please contact me.

INVOICE

22635

Maggie Machen Lamy, DVM
Diplomate of the American College of Veterinary Internal Medicine (Cardiology)
info@sonopath.com

DATE

2/17/22